

Túri Állatkórház, Kecskemét

6000 Kecskemét, Búzavirág utca 46.
Telephone: +36303791135
Fax:
Website: www.turiallatkorhaz.hu
Medical Director: Dr. Túri Ákos



Name: Sánta Csilla, Bushido
ID: 939000010947925
DOB: 02/03/2020 **Age:** 1Months
Gender: Male

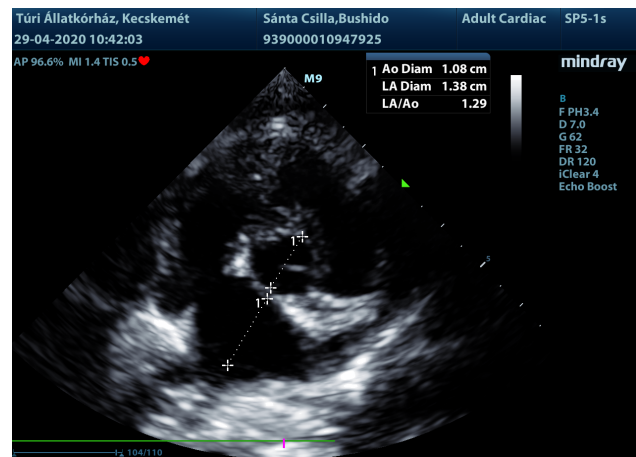
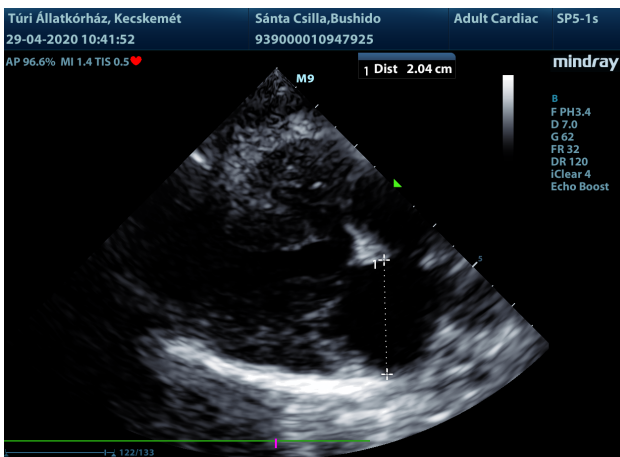
Adult Abdomen

Exam Date: 29/04/2020
Equipment Used: Mindray M9

Abdomen - 1 / 3 Page

	Value	1	2	3	4	5	6	Method
2D Measurements								
Right Kidney								
Renal L	5.71cm							Avg
Cortex	0.52cm							Avg
Left Kidney								
Renal L	4.99cm							Avg
Cortex	0.63cm							Avg

Ultrasound Image

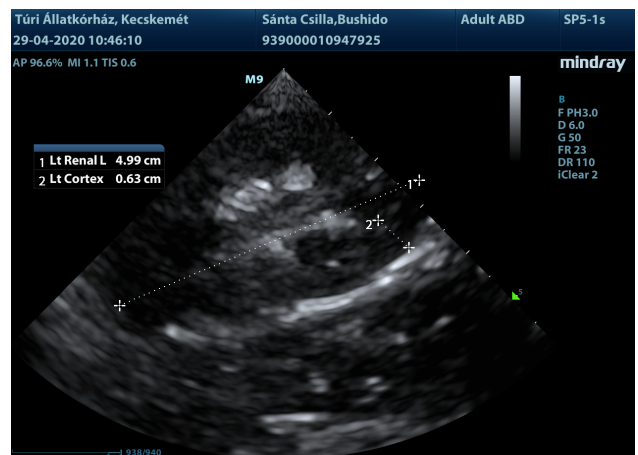
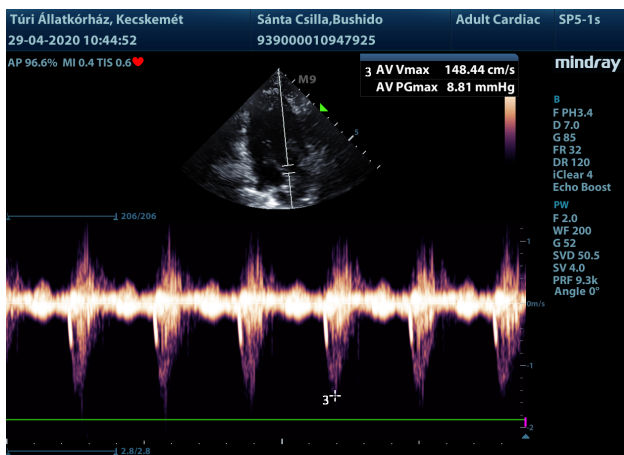
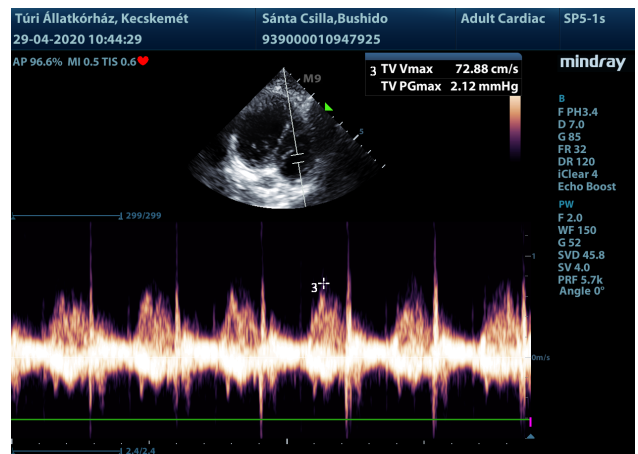
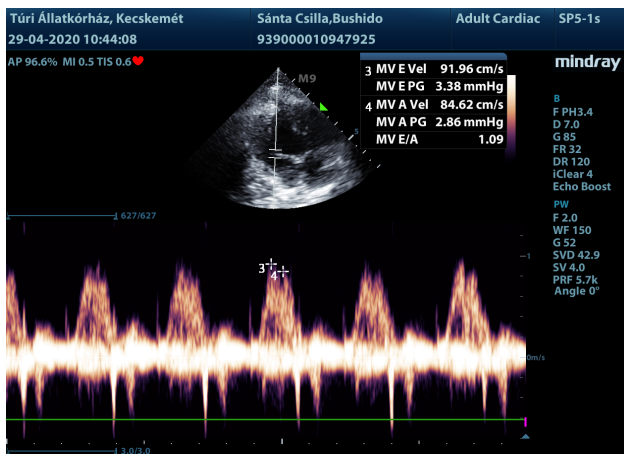
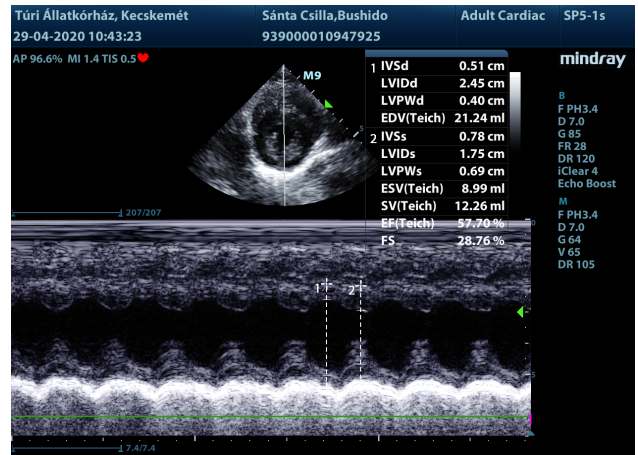
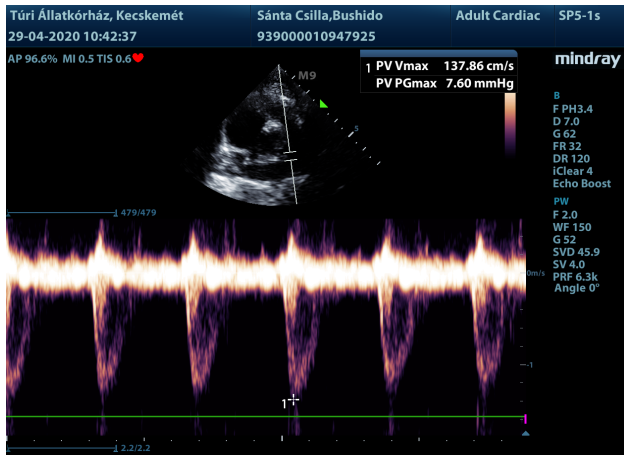




Name: Sánta Csilla, Bushido
ID: 939000010947925 DOB: 02/03/2020 Age: 1Months Gender: Male
Adult Abdomen
Exam Date: 29/04/2020

Abdomen - 2 / 3 Page

Ultrasound Image





Name: Sánta Csilla,Bushido

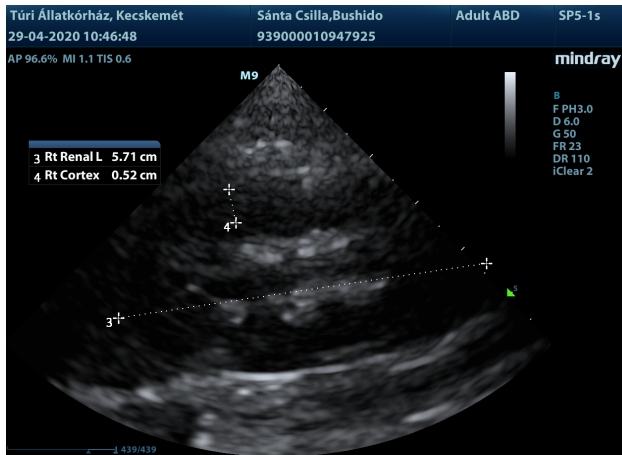
ID: 939000010947925 DOB: 02/03/2020 Age: 1Months Gender: Male

Adult Abdomen

Exam Date: 29/04/2020

Abdomen - 3 / 3 Page

Ultrasound Image



Comments:

Szív ultrahang vizsgálati lelet:

Normal tagassagu szivuregek es normal vastagsagu szivfalak merhetoek. A billentyuk normal vastagsaguak es jól zárodnak.

A szív pumpafunkciója normal. Normal rovidulesi hanyados merheto az M-mod vizsgálatnál. Normal aramlasi sebességek merhetoek a Doppleres aramlas vizsgálatnál.

Hasi ultrahang lelet: normal nagysagu, normal hosszusag/keregvastagsag aranyu vesek lathatoak a hasi ultrahang vizsgálat során.

Normal echocardiology result.

Normal valves, normal largements of the atriums and ventriculums. Normal bloodflow rates could be measured by Doppler flowmetry

Normal pictures of the kidneys could be measured

Signature(seal):

Date Signed: