

Túri Állatkórház, Kecskemét

6000 Kecskemét, Búzavirág utca 46.
Telephone: +36303791135
Fax:
Website: www.turiallatkorhaz.hu
Medical Director: Dr. Túri Ákos



Name: Sánta Csilla,Banzai
ID: 939000010947927
DOB: 02/03/2020 **Age:** 1Months
Gender: Male

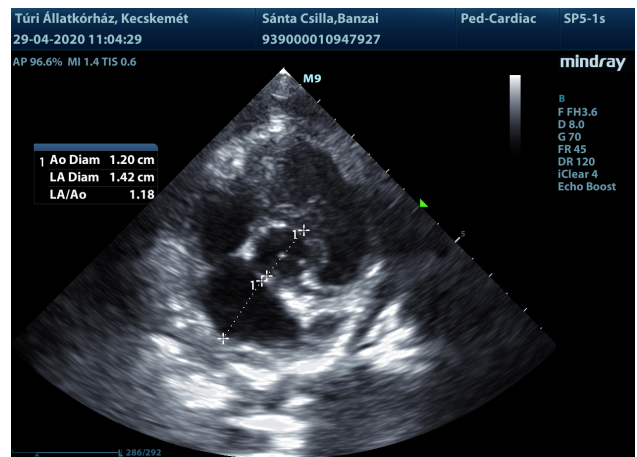
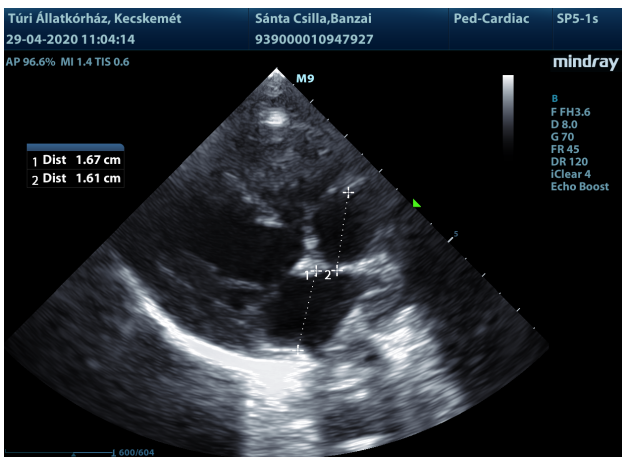
Adult Abdomen

Exam Date: 29/04/2020
Equipment Used: Mindray M9

Abdomen - 1 / 3 Page

	Value	1	2	3	4	5	6	Method
2D Measurements								
Right Kidney								
Renal L	6.73cm	6.73						Avg
Cortex	0.75cm	0.75						Avg
Left Kidney								
Renal L	5.88cm	5.88						Avg
Cortex	0.69cm	0.69						Avg

Ultrasound Image

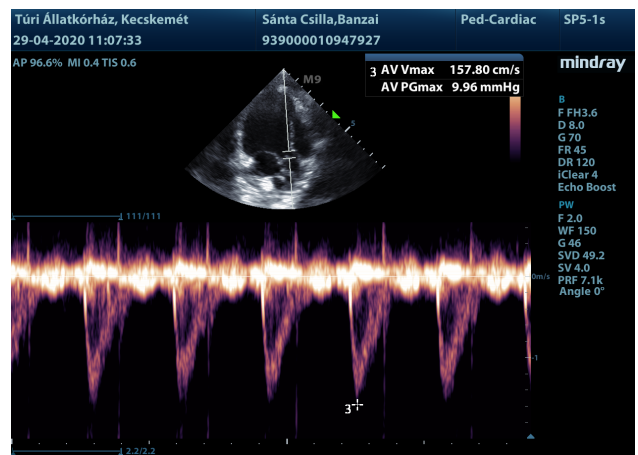
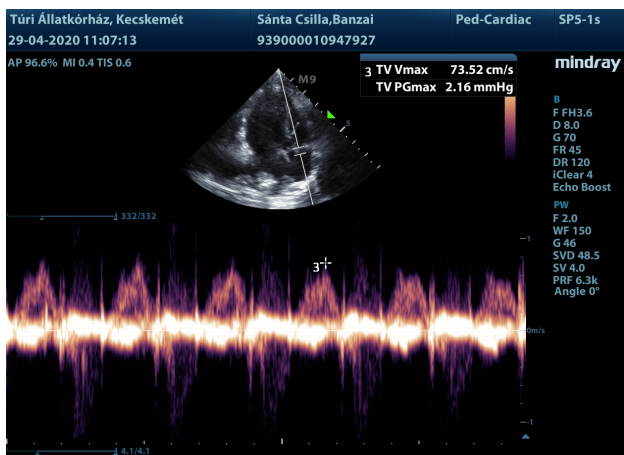
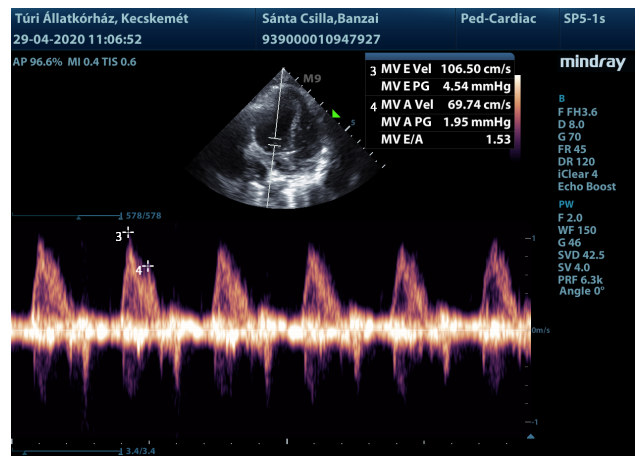
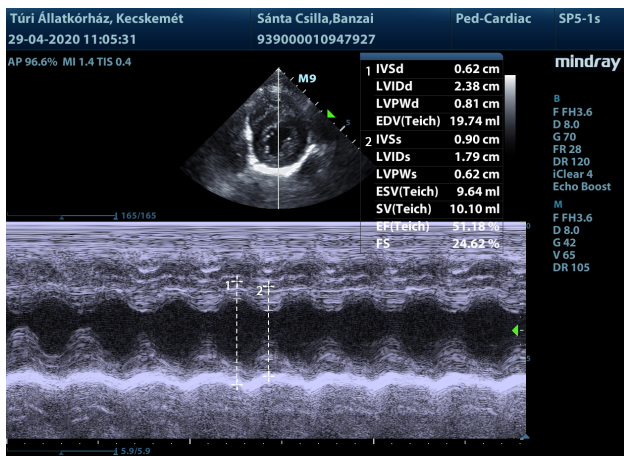
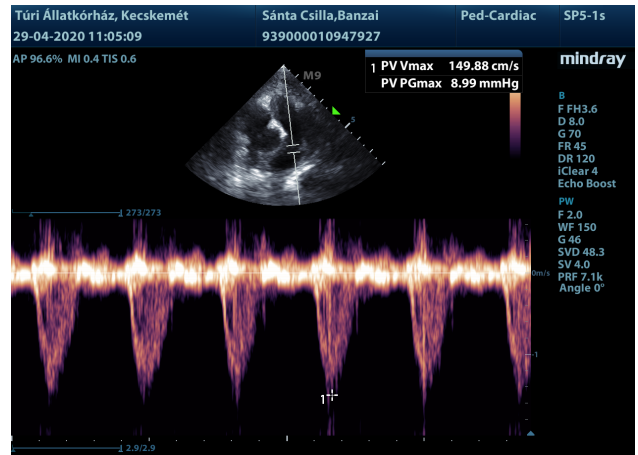
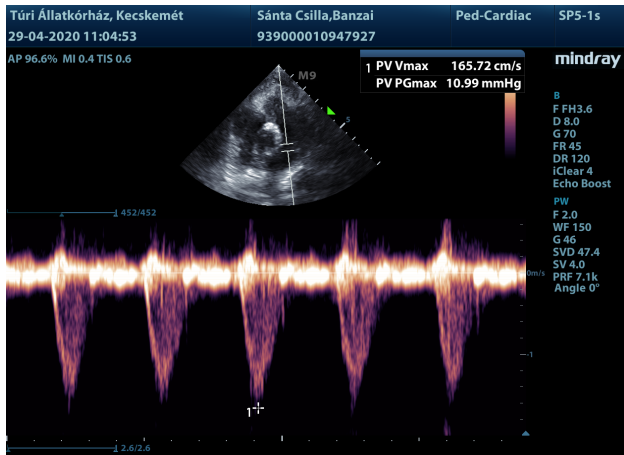




Name: Sánta Csilla,Banzai
ID: 939000010947927 DOB: 02/03/2020 Age: 1Months Gender: Male
Adult Abdomen
Exam Date: 29/04/2020

Abdomen - 2 / 3 Page

Ultrasound Image

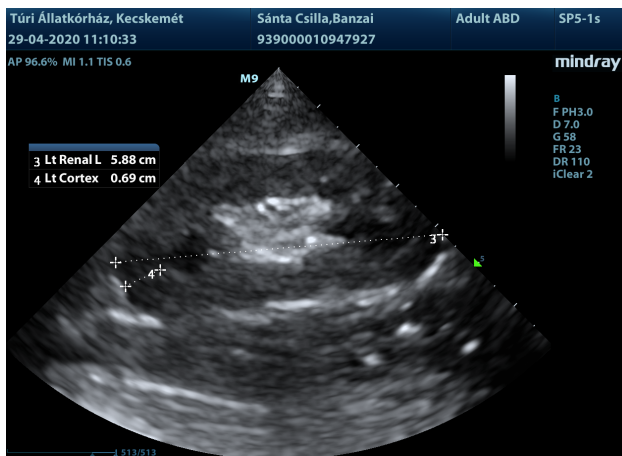
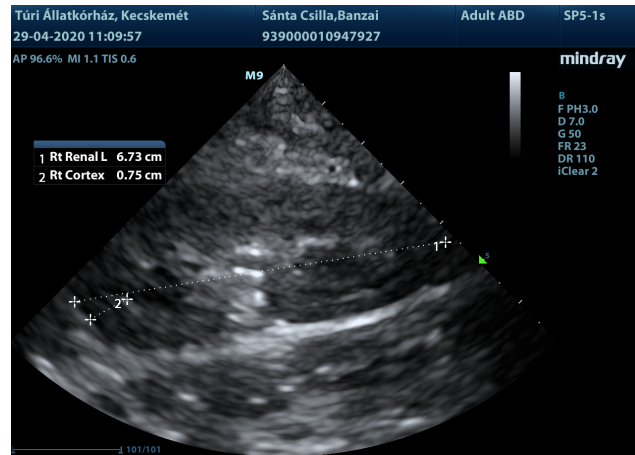
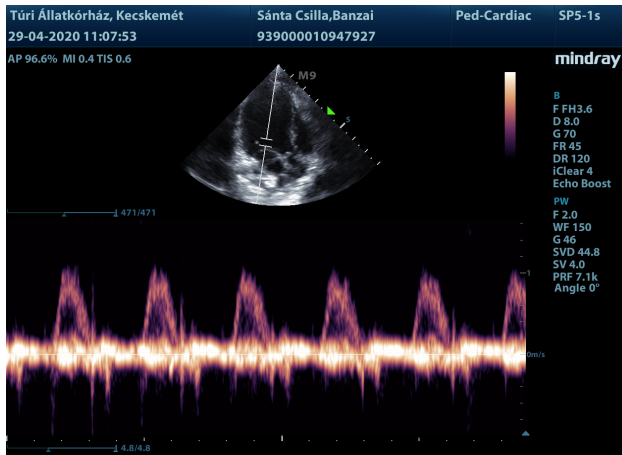




Name: Sánta Csilla,Banzai
ID: 939000010947927 DOB: 02/03/2020 Age: 1Months Gender: Male
Adult Abdomen
Exam Date: 29/04/2020

Abdomen - 3 / 3 Page

Ultrasound Image



Comments:

Szív ultrahang vizsgálati lelet:

Normal tagassagu szivuregek es normal vastagsagu szivfalak merhetoek. A billentyuk normal vastagsaguak es jól zárodnak.

A szív pumpafunkcioja normal. Normal rovidulesi hanyados merheto az M-mod vizsgálatnal. Normal aramlasi seb essegek merhetoek a Doppleres aramlas vizsgálatnal.

Hasi ultrahang lelet: normal nagysagu, normal hosszusag/keregvastagsag aranyu vesek lathatoak a hasi ultrahang vizsgálat során.

Signature(seal):

Date Signed: